

## ACUTE SKIN FAILURE AND PRESSURE INJURY IN THE PATIENT WITH COVID-19

Aline de Oliveira Ramalho<sup>1,2,\*</sup> , Talita dos Santos Rosa<sup>1</sup> ,  
Vera Lúcia Conceição de Gouveia Santos<sup>1</sup> , Paula Cristina Nogueira<sup>1</sup> 

### ABSTRACT

**Objective:** report the case of a critical patient with COVID-19 and show the main findings related to the injury considered acute skin failure (ASF), as well as perform his differential diagnosis with preventable pressure injury (PI). **Method:** observational, longitudinal, case report type study, developed in a hospital in São Paulo, in the intensive care unit (ICU) exclusively for people diagnosed with COVID-19. Data were collected from a single patient between March and September 2020. **Results:** A patient with complications from COVID-19 developed a skin lesion, initially defined as PI and later reclassified as ASF. The following findings corroborated the diagnosis: prolonged invasive mechanical ventilation, respiratory, renal and cardiac insufficiency and sepsis of respiratory focus. In addition, other aggravating factors, such as the use of vasoactive drugs, hemodynamic instability with intolerance to minimal repositioning, prolonged fasting and disseminated intravascular coagulopathy associated with coronavirus infection. **Conclusion:** the report shows that there are difficulties for the differential diagnosis between ASF and PI in clinical practice. This is a new concept, and it is essential that health professionals recognize the main factors associated with the appearance of ASF, many of which are also related to the development of PI, highlighting the need for individualized analysis of these injuries, and ensuring the implementation of interventions for prevention and treatment.

**DESCRIPTORS:** Pressure injury. Coronavirus infections. Nursing care. Intensive care units. Stomatherapy.

## ACUTE SKIN FAILURE E LESÃO POR PRESSÃO EM PACIENTE COM COVID-19

### RESUMO

**Objetivo:** relatar o caso de um paciente crítico com COVID-19 e mostrar os principais achados relacionados à lesão considerada *Acute skin failure* (ASF), bem como realizar seu diagnóstico diferencial com lesão por pressão (LP) evitável. **Método:** estudo observacional do tipo relato de caso, desenvolvido em um hospital de São Paulo, na unidade de terapia intensiva (UTI) exclusiva a pessoas diagnosticadas com COVID-19. Os dados foram coletados de um único paciente, entre os meses de março e setembro de 2020. **Resultados:** paciente com complicações da COVID-19 evoluiu com lesão de pele, inicialmente definida como LP e posteriormente reclassificada como ASF. Os seguintes achados corroboraram o diagnóstico: ventilação mecânica invasiva prolongada, insuficiências respiratória, renal e cardíaca e sepse de foco respiratório. Além disso, outros fatores agravantes, como o uso de droga vasoativa, instabilidade hemodinâmica com intolerância ao mínimo reposicionamento, jejum prolongado

1. Universidade de São Paulo – Escola de Enfermagem – São Paulo (SP), Brazil.

2. Hospital Sírio Libanês – São Paulo (SP), Brazil.

\*Correspondence author: [alineo\\_ramalho@hotmail.com](mailto:alineo_ramalho@hotmail.com)

Section Editor: Juliano Teixeira Moraes

Received: Dez. 23, 2020 | Accepted: Fev. 08, 2021

How to cite: Ramalho AO; Rosa TS; Santos VLCG; Nogueira PC. Acute skin failure and pressure injury in the patient with COVID-19. ESTIMA, Braz. J. Enterostomal Ther., 2021, 19: e0521. [https://doi.org/10.30886/estima.v19.1007\\_IN](https://doi.org/10.30886/estima.v19.1007_IN)

e coagulopatía intravascular diseminada asociada à infecção pelo coronavírus. **Conclusão:** o relato mostra que existem dificuldades para o diagnóstico diferencial entre ASF e LP na prática clínica. Trata-se de conceito novo, sendo fundamental que o profissional de saúde reconheça os principais fatores associados ao aparecimento da ASF, muitos dos quais também estão relacionados ao desenvolvimento das LP, ressaltando a necessidade de análise individualizada dessas lesões, e garantia da implementação de intervenções adequadas para prevenção e tratamento.

**DESCRITORES:** Lesão por pressão. Infecções por coronavírus. Cuidados de enfermagem. Unidades de terapia intensiva. Estomaterapia.

## ACUTE SKIN FAILURE Y LESIÓN POR PRESIÓN EN EL PACIENTE CON COVID-19

### RESUMEN

**Objetivo:** Informar los principales hallazgos en un paciente con COVID-19 ingresado en una unidad de cuidados intensivos (UCI), que desarrolló una lesión considerada Insuficiencia cutánea aguda (PPA), así como diferenciar la lesión por presión (LP) de la PPA. **Método:** estudio observacional, longitudinal y descriptivo, del tipo reporte de caso, desarrollado en un hospital de São Paulo, en la UCI exclusivamente para personas diagnosticadas con COVID-19, entre los meses de marzo a septiembre de 2020. La muestra estuvo conformada por un paciente.

**Resultados:** Un paciente con complicaciones por COVID-19, evoluciona con una lesión cutánea, inicialmente definida como LP, sin embargo, reclasificada como ASK. Los hallazgos que corroboran el diagnóstico fueron: Ventilación mecánica invasiva prolongada, insuficiencia respiratoria, renal y cardíaca y sepsis del foco respiratorio. Además, factores agravantes como el uso de fármacos vasoactivos, inestabilidad hemodinámica con intolerancia al reposicionamiento mínimo, ayuno prolongado, historia clínica con varias comorbilidades y coagulopatía intravascular diseminada inducida por infección por coronavirus. **Conclusión:** El informe muestra que existen dificultades para el diagnóstico diferencial entre PPA y PL en la práctica clínica. Es un concepto novedoso, y es fundamental que el profesional de la salud reconozca los principales factores asociados a la aparición de la PPA, muchos de los cuales también están relacionados con el desarrollo de LP, destacando la necesidad de un análisis individualizado de estas lesiones y asegurando la implementación de intervenciones adecuadas, para la prevención y el tratamiento.

**DESCRIPTORES:** Úlcera por Presión. Infecciones por Coronavirus. Atención de Enfermería. Unidades de Cuidados Intensivos. Estomaterapia.

## INTRODUCTION

The new coronavirus (SARS-COV-2), discovered in December 2019, caused a pandemic of great impact, due to its high ability to spread through contact and droplets. The infection caused by it, also called COVID-19, has different clinical manifestations, ranging from asymptomatic infection to severe acute respiratory syndrome (SARS), usually with uncertain prognosis that can result from hospitalization, often in a intensive care unit (ICU) to fatal outcome<sup>1</sup>.

It is believed that the main mechanisms responsible for severity in these patients are related to the exacerbated release of inflammatory mediators and the dysregulation of the coagulation system, which favors the development of SARS and predisposes to the need for respiratory support, in addition to clinical and hemodynamic instability<sup>2</sup>.

Due to the severity of the affected patients, the exorbitant increase in hospital admissions, increased demand for invasive respiratory support, increased hospital stay and the need for multiple devices and therapies for the recovery of these patients<sup>1,2</sup>, health services felt pressured, costs increased too much and there was an overload of work by health teams, characterizing an almost chaotic world panorama.

In view of the complexity found in these patients, some may evolve with multiple organ failure, with skin lesions occurring concomitantly, usually in areas exposed to pressure. In this context, the National Pressure Injury Advisory Panel (NPIAP) has specifically positioned itself on the risks for the development of pressure injuries (PI), considering also the important increase in its occurrence. The panel recognizes that the profile of the patient with COVID-19 is different from what we saw previously, drawing attention to the pathophysiological aspects of the disease that corroborate the appearance of skin lesions, highlighting systemic coagulopathy, hypercatabolism and nutritional deficit, as well as the tendency of these patients to clinical and hemodynamic instability, the need for prone positioning and the use of multiple health care devices. The organization also emphasizes the existence of institutional problems related to work overload, the lack of time to prepare the hired labor and the difficulties to purchase and use products aimed at preventing PI<sup>3</sup>.

The occurrence of PI is often related to the break in skin care protocols or the lack of protocols based on scientific evidence, reflecting not only the quality of nursing care but the excellence of the health system as a whole<sup>4</sup>. Most cases are considered to be preventable<sup>5,6</sup>. Although there are some circumstances that inevitably favor the development of PI, it should only be considered as such when it occurs even after the correct assessment of the patient at risk and the implementation of all evidence-based prophylactic interventions<sup>5-7</sup>.

Numerous terminologies are used for unavoidable skin ulcers, such as Kennedy's terminal ulcer, Trombley-Brennan lesions, Skin Changes at Life's End (SCALE), unavoidable pressure injury, among others<sup>8,9</sup>. In 2017, Levine<sup>10</sup> suggested the use of the nomenclature Skin Failure as an "umbrella" term for injuries that result from the patient's terminality and severity, with poor tissue perfusion, which can be classified into acute, chronic or related to the final stage of life.

Skin failure is a unifying concept defined by low tissue tolerance and other factors, including hypoxia, ischemia, decreased nutrient delivery and decreased clearance of toxic metabolites that can promote the development of a reperfusion injury<sup>10</sup>.

Acute Skin Failure (ASF) does not have a clear definition in the literature, however, several authors<sup>7,8,10,11</sup> refer to skin damage resulting from an acute process, in general, with clinical and hemodynamic instability, limiting the supply of nutrients and oxygen to this organ. These injuries usually occur due to tissue hypoxia, and can affect any area of the body, not necessarily in bone prominence. Predictors of its onset are prolonged mechanical ventilation (> 72h), multiple organ failure (2 or more compromised systems), the presence of peripheral arterial disease and sepsis or septic shock<sup>12,13</sup>. Chronic skin failure occurs as a result of pre-existing chronic disease. End-of-life skin failure includes SCALE and Kennedy terminal ulcers<sup>7,8,10,14,15</sup>.

Bearing in mind that the injuries included in the Skin Failure concept are developed even after the implementation of appropriate preventive measures to the patient's risk for PI, it is essential to carry out a global assessment of this event, considering not only the clinical aspects of the patient, but also topics related to the hospital institution in which it is located. These topics refer to the existence of adequate and updated protocols for the prevention of skin injuries, adherence of the team to preventive measures, appropriate notes in the medical record and inclusion of justifications for their non-execution when indicated<sup>8,14,15,16</sup>. In addition, organizational factors must also be analyzed, such as available material and human resources, adequate logistics for carrying out prevention strategies, among others.

Despite these and other recommendations and statements, such as those recently established by the NPIAP and some of which have already been adopted in the country<sup>17</sup>, the available literature does not yet provide scientific evidence that can directly associate COVID-19 infection and the development of skin lesions resulting or not from pressure<sup>3</sup>.

As mentioned before, even with all existing recommendations, clinical practice has shown a relevant number of lesions in areas of bone prominence, with an ischemic aspect, similar to deep tissue (DTPI) in patients with COVID-19, developed during invasive use of ventilation mechanics, hemodynamic instability, use of vasoactive

drugs, multiple organ failure, among other factors already known as predictors for the development of ASF. In these cases, the challenge is to make the differential diagnosis between PI and ASF.

ASF is still little discussed in the literature, making it difficult to differentiate it from preventable PI in daily practice. It is extremely important to perform the differential diagnosis, since preventable PI is considered an adverse event related to health care, liable to legal and economic impact, and shows the fragility of institutional quality, unlike the ASF that do not compose the indicators of quality and should be excluded from the numerator of the PI indicator<sup>8,11,18</sup>.

This article aims to report the case of a critical patient with COVID-19 and to show the main findings related to the lesion considered ASF, as well as to make its differential diagnosis with avoidable pressure injury.

## METHOD

This is an observational, longitudinal, case report type study developed in the ICU exclusively for people diagnosed with COVID-19, in a large philanthropic hospital located in the city of São Paulo, between the months of March and September of 2020. The sample consisted of a single patient, diagnosed with COVID-19 and ASF, whose case was extracted from a retrospective cohort study that assessed the incidence of PI and clinical outcome in people affected by COVID-19. The study was approved by the hospital's Research and Ethics Committee (Opinion No. 4.462260), based on resolution 466/2012 of the National Health Council/Ministry of Health. The researchers received the consent of the family member responsible for the patient, since he was in a coma. The Free and Informed Consent Term was applied for the use of images of the evolution of the lesion, in two ways.

## RESULTS

The following is a summary of the case studied with emphasis on aspects of differentiation between ASF and DTPI.

### Clinical case

A.Z, 76 years old, was admitted on March 23, 2020 due to the presence of cough for 6 days, high fever and dyspnea, being diagnosed with SARS related to the infection by the new coronavirus. He had the following health history: systemic arterial hypertension, obstructive heart failure, diabetes mellitus, dyslipidemia, hypothyroidism and obesity. After two days of hospitalization, he developed a worsening of the breathing pattern, being transferred to the ICU and submitted to orotracheal intubation and invasive mechanical ventilation, which remained until the end of hospitalization. Four days after hospitalization, he developed respiratory sepsis requiring the use of vasoactive drugs (norepinephrine 0.1 mcg/kg/min, with increasing dose up to 0.6 mcg/kg/min), remaining on prolonged fasting (> 72h) and anasarca. He developed acute renal failure, receiving conservative treatment. On April 4, he had disseminated intravascular coagulation (DIC) and signs of intracranial hypertension, being treated with unfractionated heparin.

In addition to these changes, in the first days in the ICU he presented important hemodynamic instability, with intolerance to repositioning (oxygen desaturation of up to 76% during mobilization). As a solution to the mobilization, the electronic resource of the bed was used, which allows the patient to gradually lateralize and relieve pressure points. However, he maintained desaturation and hypotension with an angle <10 degrees, having to remain in the same position for approximately 48 hours.

On April 7, 2020, a lesion with an ischemic characteristic was detected in the bilateral gluteal region, initially defined as deep tissue PI (Fig. 1). Table 1 shows the laboratory tests and parameters of invasive mechanical ventilation during the ICU stay, before and after the appearance of the lesion in the gluteal region.

**Table 1.** Laboratory tests and parameters of invasive mechanical ventilation in the three evaluation periods: admission to the intensive care unit, before and after the injury. São Paulo (SP), Brasil – 2020.

Hemodynamic parameters	03.25.2020 – Admission to the intensive care unit	04.04.2020 – 72h before the appearance of the injury	04.07.2020 – Injury identification
Hemoglobine	14.4g/dL	8.2 g/dL	8.6 g/Dl
Arterial blood gases	pH: 7.40 pO <sup>2</sup> : 88 mmHg pCO <sup>2</sup> : 40 mmHg HCO <sup>3</sup> : 24 mmol/L BE: 0.1 SO <sup>2</sup> : 97%	pH: 7.33 pO <sup>2</sup> : 89 mmHg pCO <sup>2</sup> : 62 mmHg HCO <sup>3</sup> : 31 mmol/L BE: 5.2 SO <sup>2</sup> : 96%	pH: 7.42 pO <sup>2</sup> : 79 mmHg pCO <sup>2</sup> : 52 mmHg HCO <sup>3</sup> : 34 mmol/L BE: 8.5 SO <sup>2</sup> : 95%
D-dimer	1583 ng/mL FEU	6522 ng/mL FEU	5420 ng/mL FEU
PCR	4.14 mg/dL	4.80 mg/dL	8.80 mg/Dl
Creatinine	1.38 mg/dL	3.00 mg/dL	1.29 mg/dL
Urea	56 mg/dL	272 mg/dL	151 mg/dL
Parameters of invasive mechanical ventilation			
Respiratory Parameters	Mode PCV (PC 11; PEEP 10; FIO <sup>2</sup> 60%; 24/24 bpm; IT 0,85/ TV 330mL), EtCO <sup>2</sup> 27, synchronous to MV.	Mode VCV (PEEP 12; 30/30 bpm; IT 0,61; FIO <sup>2</sup> 45%; TV 360ml), EtCO <sup>2</sup> 43, synchronous to MV.	Mode VCV (PEEP 08; IT 0,58; FIO <sup>2</sup> 60%, 24/24 bpm; TV 400ml; drive pressure 7; complacency 57; resistance 7.7; Peak pressure 25; Plateau pressure 15), EtCO <sup>2</sup> 40, synchronous to MV.

pH = Hydrogen Potential; pO<sup>2</sup> = Oxygen Partial Pressure; PCR = Polymerase Chain Reaction; pCO<sup>2</sup> = Carbon Gas Partial Pressure; HCO<sup>3</sup> = Basic Bicarbonate; FIO<sup>2</sup> = Inspired Oxygen Fraction; BE = Base Excess; SO<sup>2</sup> = Oxygen Hemoglobin Saturation; FEU = Equivalent Fibrinogen Units; PEEP = Final Expiratory Positive Pressure; VCV = Volume Controlled Ventilation; PCV/PC = Controlled Pressure; bpm = Breaths per Minute; IT = Inspiratory Time; TV = Tidal Volume; MV = Mechanical ventilation; EtCO<sup>2</sup> = Maximum Carbon Dioxide Concentration at the End of a Breath.

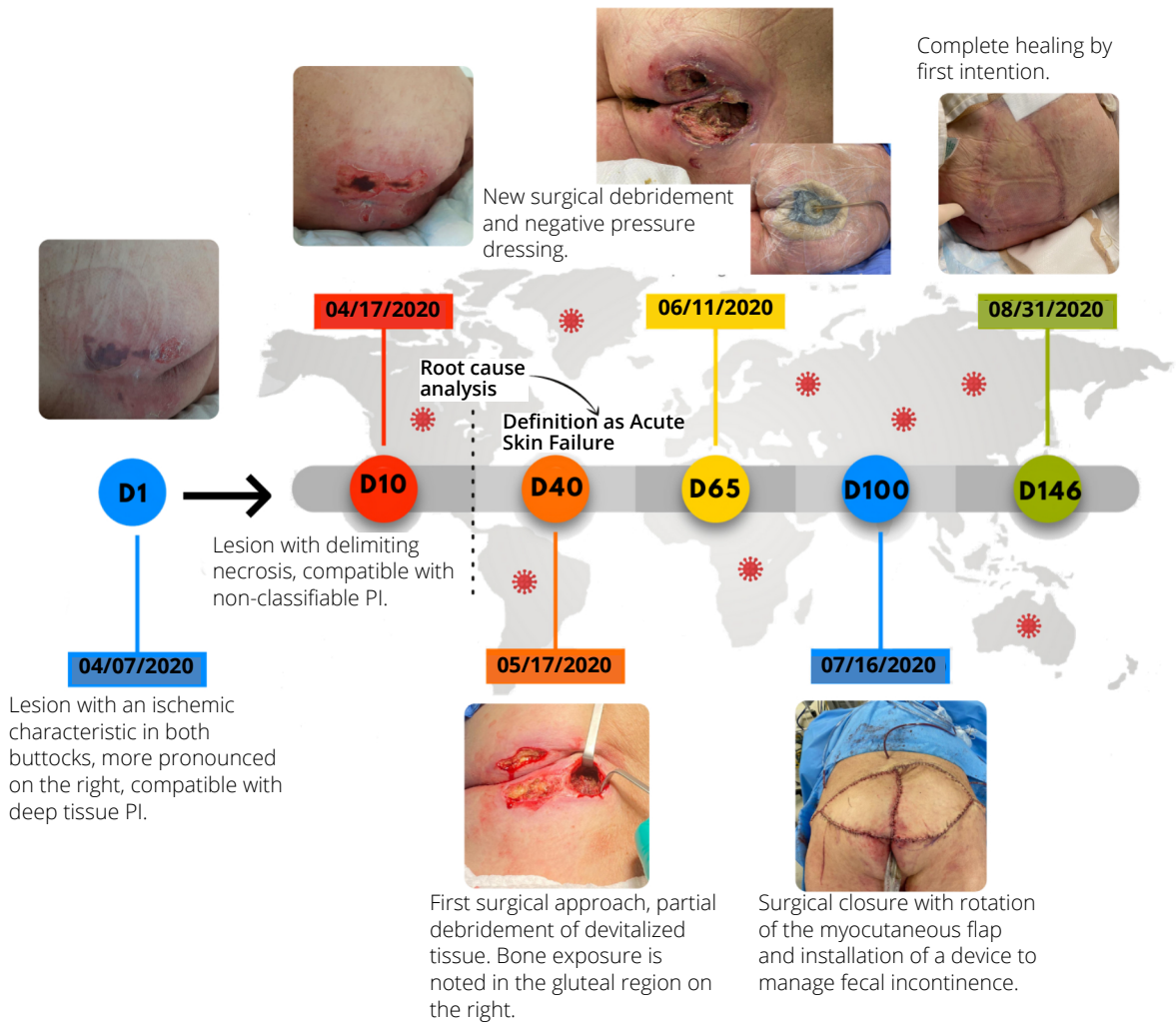
## Injury evolution

After clinical stabilization, bedside approaches by the stomatherapist began. As an initial conduct, a protocol for the evolutionary observation of the lesion and protection of the affected area was established with multilayer, silicone-adhesive polyurethane foam dressing, in addition to maintaining topical care, according to the patient's needs, and reinforcement in the guidelines for the team, mainly aiming at the redistribution of the mechanical load and consequent reduction of pressure in the area (Fig. 1 - D1 to D10).

According to the delimitation of the ischemic area and the evolution of the affected area to necrosis, applications of hydrofiber with silver and hydrogel were performed, aiming at the vertical absorption of exudate, moisture management and aid in autolytic debridement, associated with high technology dressings (multilayer, silicone-adhesive polyurethane foam dressing) (Fig. 1 - D10 to D40).

An evaluation was requested from the plastic surgery team, which opted for partial debridement of the lesion in the operating room (D40) and later a two-stage surgical approach, with debridement and installation of negative-pressure wound therapy (NPWT) (D65) first focusing on the preparation of the woundbed and in the complete closure of the affected area, in the second stage (D100), using a large extension myocutaneous flap (See Fig. 1).

After surgical treatment, care was directed to complete healing of the wound and protection of the area, mitigating the risks of developing complications from the surgical wound and new PI. The patient remained in the ICU due to dependence on mechanical ventilation and neurological sequelae. In August, he presented a new case of sepsis with a respiratory focus, with a worsening of the clinical and hemodynamic condition, progressing to death after 166 days of hospitalization



**Figure 1.** Infographic of the clinical evolution of Acute Skin Failure as a result of COVID-19 in a patient admitted to the intensive care unit. São Paulo (SP), Brasil – 2020.

As per institutional routine, all adverse events that cause moderate and severe damage to the patient must be analyzed and process improvement plans implemented, according to each weakness found. In this case, the root cause analysis was conducted by the stomatherapist nurses from the institution and the skin integrity committee (multi professional team), together with the patient safety unit.

In this analysis, it was identified that the preventive measures recommended in the institutional protocol were applied, considering the patient’s safety and tolerance, and justified, in medical records, those, pertinent to the presented clinical picture, that could not be applied.

Therefore, considering the presence of clinical and hemodynamic instability, minimal intolerance to repositioning, systemic coagulopathy, deficit of oxygenation due to coronavirus infection, presence of sepsis, prolonged ICU stay and invasive mechanical ventilation, use of vasoactive drugs, as well like multiorgan dysfunction (respiratory, cardiac and acute renal), the lesion can be characterized and established as ASF, excluding the case of the incidence and prevalence indicators of PI in the institution.

## DISCUSSION

Within the pandemic context of COVID-19, the services of stomatherapy and wound prevention and treatment groups of various organizations underwent modifications and restructuring, aiming to implement and subsidize an

innovative and comprehensive clinical practice for patients in general. These services have adapted and acted efficiently even in the face of a scenario of uncertainty<sup>19,20</sup>. Despite this, there is a significant increase in the number of patients with skin lesions, most often defined as PI, although not always constituting the most assertive diagnosis.

In this case report, there was a great effort by the multiprofessional team to properly manage the patient and to implement PI prevention strategies. Prevention interventions were applied according to the institutional protocol, based on the recommendations of international societies<sup>16,21</sup>, including: daily assessment of the risk of developing PI, using the Braden scale; frequent skin inspection; repositioning according to the patient's tolerance; use multilayer, silicone-adhesive polyurethane foam dressing as a prophylactic cover; support surface with viscoelastic foam and alternating pressure; moisture management; nutritional assessment and intervention, among others. Even with the interventions applied, the patient developed an injury initially defined as a DTPI that ended up being definitively diagnosed as ASF, after a more detailed analysis in which the changes caused by COVID-19 were also considered.

The differential diagnosis of skin lesions is a challenge, especially in the critical environment. On the one hand, one must have the differential diagnosis of confounding injuries, on the other, there is a constant struggle to prevent PI prevention from becoming trivialized and seen as impossible within the ICU. Thus, once PI has been identified, NPIAP recommends the application of the root cause analysis tool for injuries acquired in the hospital environment, especially analyzing the 72h period before its appearance<sup>22</sup>. This tool can assist in the differential diagnosis and in the survey of possible predictors of injuries considered inevitable and/or resulting from acute skin failure.

The differentiation between avoidable PI and ASF injury is, therefore, in the causal factor and in the implementation of preventive measures. PIs are specifically due to pressure, friction and shear in areas of bony prominence or when using medical devices<sup>21</sup>. ASF, on the other hand, have clinical and hemodynamic instabilities as the main causative factors, as they result in tissue hypoxia that affects different areas of the body, in bone prominences or not<sup>5,7,14</sup>.

In a document on aspects related to the complexity of the patient with COVID-19 and the emergence of inevitable PI published by NPIAP in 2020<sup>3</sup>, early in the pandemic, the pathophysiology of the virus, the patient's instability and the intrinsic and extrinsic risk factors are found to be causal, which is similar to those described for ASF, making the differential diagnosis between them even more difficult. Levine<sup>8</sup> and Ayello<sup>10</sup> et. al agree that injuries that present themselves in this critical scenario can be better defined as Skin Failure.

Differentiation and use of the term ASF in cases related to hemodynamic instability and criticality of the patient are important, both from the point of view of the clarity of information to the patient and family about the etiology of the skin lesion and perspectives of evolution, and from the institutional point of view, depending on the legal and financial impact, patient satisfaction and the quality of care provided by the health service.

Reflecting on the quality of care, certifying agencies that offer service quality seals may make access to certification difficult if the differentiation of the etiology between avoidable PI and ASF is not accurate. In this context, ASF should be excluded from the PI incidence and prevalence indicator, as its development is not only related to the care provided by the health team, but also to the clinical instability and intrinsic conditions of the patient. It is reiterated that this exclusion should be carried out only after analyzing the execution of prevention strategies in an appropriate manner and following the latest national and international recommendations<sup>21,23</sup>.

In the case reported, although the findings of mechanical ventilation parameters and arterial blood gases did not show major changes, the patient presented a marked drop in hemoglobin, a gradual increase in the Polymerase Chain Reaction (PCR) and a worsening in Creatinine and D-Dimer (Table 1), prior to the appearance of the injury. In addition, he used a vasopressor, remained on an extended fast due to instability, had anasarca and sepsis. It is also noted the worsening of ventilatory parameters (Table 1), which implied the need for neuromuscular block and there was intolerance to the minimum repositioning.

Although there is little evidence that links the pathophysiology of COVID-19 infection with skin lesions, it is known that the disease compromises tissue oxygenation and nutrition as well as favoring the development of disseminated coagulopathy, factors that can promote the occurrence of ASF<sup>3</sup>. The data presented in the present case study, that is, a picture of acute respiratory, cardiac and renal insufficiency and the use of prolonged invasive mechanical ventilation,

seem to corroborate the diagnosis of ASF when they are compatible with the factors described as predictors of this development, present in a recently published systematic review<sup>14</sup>.

The differentiation between avoidable PIs and unavoidable skin lesions, such as ASF, is a complex process and requires a detailed assessment of the findings that underlie the diagnostic decision-making in the face of injuries. After detailed analysis of the case, survey of the implementation of preventive measures proportional to the patient's risk, as well as reflection of the multidisciplinary team on the pathology, clinical condition and strategies adopted for the patient in question together with the institution's stoma therapy team, the injury, previously defined as DTPI and considered as an adverse event, was redefined as ASF.

Especially in the pandemic context in which we find ourselves, evidence-based skin injury prevention strategies are necessary, associated with the performance of a multidisciplinary team and prevention plans under special conditions, such as the prone positioning, prevention of the Medical Device Related Pressure Injury, among others<sup>3,16,17</sup>. It is crucial that the nurse and the health care team have knowledge about the predictive factors of both types of injury, as their differentiation has legal, economic and quality impacts on the institution<sup>18</sup>.

As it is a recent and rarely addressed topic, there is a shortage of literature on this topic, especially in Brazil. Added to this is the lack of validated instruments and well-established diagnostic criteria for the differentiation between PI and ASF. In this perspective, although limited by the type of study, this case report aims to contribute to the knowledge about ASF, its diagnosis and differentiation with PI, as well as to the reflection on skin failure and inevitable injuries in the practice of care.

## CONCLUSION

This case report contributes with some answers to the gaps on Skin Failure in clinical practice, mainly from specialist nurses requested for the evaluation and therapeutic planning of this type of more complex injury. Nursing and, particularly, the specialties that deal with the care of patients with wounds, need to develop research on this theme, aiming to substantiate criteria and subsidize more accurate and effective diagnoses and interventions corresponding to the types of injuries, especially in critical patients with COVID- 19.

## AUTHORS 'CONTRIBUTION

Conceptualization: Ramalho AO and Rosa TS; Methodology: Rosa TS and Ramalho AO; Writing - First Version: Ramalho AO and Rosa TS; Writing - Review & Editing: Ramalho AO, Rosa TS, Santos VLCCG and Nogueira PC; Supervision: Santos VLCCG and Nogueira PC.

## ACKNOWLEDGMENTS

To the stomatherapy group at the Hospital Sírio Libanês and the research group on stomatherapy of the School of Nursing, University of São Paulo - GPET.

## REFERENCES

1. Guan W, Ni Z, Hu Y, Liang W, Ou C, He J et al. Clinical Characteristics of Coronavirus Disease 2019 in China. *N Engl J Med* 2020;382(18):1708–20. <https://doi.org/10.1056/NEJMoa2002032>
2. Cavayas YA, Noël A, Brunette V, Williamson D, Frenette AJ, Arsenault C et al. Early experience with critically ill patients with COVID-19 in Montreal. *Can J Anesth* 2020;68:204-13. <https://doi.org/10.1007/s12630-020-01816-z>
3. Black J, Cuddigan J, Capasso V, Cox J, Delmore B, Munoz N et al. on behalf of the National Pressure Injury Advisory Panel (2020). Unavoidable Pressure Injury during COVID-19 Crisis: A Position Paper from the National Pressure Injury Advisory Panel. Available at: [https://cdn.ymaws.com/npiap.com/resource/resmgr/white\\_papers/Unavoidable\\_in\\_COVID\\_Pandemi.pdf](https://cdn.ymaws.com/npiap.com/resource/resmgr/white_papers/Unavoidable_in_COVID_Pandemi.pdf)



4. Ayello EA, Sibbald RG. Pressure Injuries: Nursing-Sensitive Indicator or Team- and Systems-Sensitive Indicator? *Adv Skin Wound Care* 2019;32(5):199-200. <https://doi.org/10.1097/01.ASW.0000557754.10070.88>
5. Edsberg LE, Langemo D, Baharestani MM, Posthauer ME, Goldberg M. Unavoidable Pressure Injury: state of the science and consensus outcomes. *J Wound Ostomy Continence Nurs* 2014;41(4):313-34. <https://doi.org/10.1097/WON.0000000000000050>
6. Schmitt S, Andries MK, Ashmore PM, Brunette G, Judge K, Bonham PA. WOCN Society Position Paper: Avoidable Versus Unavoidable Pressure Ulcers/Injuries. *J Wound Ostomy Continence Nurs* 2017;44(5):458-68. <https://doi.org/10.1097/WON.0000000000000361>
7. Sibbald RG, Ayello EA. Terminal Ulcers, SCALE, Skin Failure and Unavoidable Pressure Injuries: Results of the 2019 Terminology Survey. *Adv Skin Wound Care* 2020;33(3):137-45. <https://doi.org/10.1097/01.ASW.0000653148.28858.50>
8. Ayello EA, Levine JM, Langemo D, Kennedy-Evans KL, Brennan MR, Sibbald RG. Reexamining the Literature on Terminal Ulcers, SCALE, Skin Failure and Unavoidable Pressure Injuries. *Adv Skin Wound Care* 2019;32(3):109-21. <https://doi.org/10.1097/01.ASW.0000553112.55505.5f>
9. Langemo DK, Brown G. Skin Fails Too: Acute, Chronic, and End-Stage Skin Failure. *Adv Skin Wound Care* 2006;19(4):206-11. <https://doi.org/10.1097/00129334-200605000-00014>
10. Levine JM. Unavoidable Pressure Injuries, Terminal Ulceration, and Skin Failure: In Search of a Unifying Classification System. *Adv Skin Wound Care* 2017;30(5):200-2. <https://doi.org/10.1097/01.ASW.0000515077.61418.44>
11. Delmore B, Cox J, Rolnitzky L, Chu A, Stolfi A. Differentiating a pressure ulcer from acute skin failure in the adult critical care patient. *Adv Skin Wound Care* 2015;28(11):514-24. <https://doi.org/10.1097/01.ASW.0000471876.11836.dc>
12. Nowicki JL, Mullany D, Spooner A, Nowicki TA, Mckay PM, Corley A et al. Are pressure injuries related to skin failure in critically ill patients? *Aust Crit Care* 2018;31(5):257-63. <https://doi.org/10.1016/j.aucc.2017.07.004>
13. Delmore B, Cox J, Smith D, Chu AS, Rolnitzky L. Acute Skin Failure in the Critical Care Patient. *Adv Skin Wound Care* 2020;33(4):192-201. <https://doi.org/10.1097/01.ASW.0000604172.69953.23>
14. Dagleish L, Campbell J, Finlayson K, Coyer F. Acute Skin Failure in the Critically Ill Adult Population: A Systematic Review. *Adv Skin Wound Care* 2020;33(2):76-83. <https://doi.org/10.1097/01.ASW.0000617844.69248.92>
15. Sibbald RG, Krasner DL, Lutz JB, Sylvia C, Alvarez O, Ayello EA et al. The SCALE Expert Panel: Skin Changes At Life's End. Final Consensus Document. 2009.
16. European Pressure Ulcer Advisory Panel, National Pressure Injury Advisory Panel and Pan Pacific Pressure Injury Alliance. Prevention and Treatment of Pressure Ulcers: Quick Reference Guide. EPUAP, NPIAP, PPPIA: 2016.
17. Ramalho AO, Freitas PSS, Moraes JT, Nogueira PC. Reflexões sobre as recomendações para prevenção de lesões por pressão durante a pandemia de covid-19. *ESTIMA, Braz. J. Enterostomal Ther.*, 2020, 18: e2520. [https://doi.org/10.30886/estima.v18.940\\_PT](https://doi.org/10.30886/estima.v18.940_PT)
18. Kim JH, Shin HK, Jung GY, Lee DL. A case of acute skin failure misdiagnosed as a pressure ulcer, leading to a legal dispute. *Arch Plast Surg* 2019;46(1):75-8. <https://doi.org/10.5999/aps.2018.00087>
19. Gray M. Context for Practice: WOC Specialty Practice at the Front Lines during a Global Pandemic. *J Wound Ostomy Continence Nurs* 2020;47(4):309-10. <https://doi.org/10.1097/WON.0000000000000670>
20. Pontieri-Lewis V. Adapting WOC Nursing Practice to the COVID-19 Pandemic: A View from Here. *J Wound Ostomy Continence Nurs* 2020;47(4):321-3. <https://doi.org/10.1097/WON.0000000000000667>
21. European Pressure Ulcer Advisory Panel, National Pressure Injury Advisory Panel and Pan Pacific Alliance. Prevention and Treatment of Pressure Ulcers/Injuries: Quick Reference Guide. Emily Haesler (Ed.). EPUAP/NPIAP/PPPIA:2019.
22. Black JM. Root Cause Analysis for Hospital-Acquired Pressure Injury. *J Wound Ostomy Continence Nurs* 2019;46(4):298-304. <https://doi.org/10.1097/WON.0000000000000546>
23. Almeida LV de, Bizutti NS, Draganov PB. Impactos da acreditação Magnet Recognition nos serviços de enfermagem: uma revisão narrativa. *Rev Adm Saúde (On-Line)* 2019;19(77):e198. <https://doi.org/10.23973/ras.77.198>