







## USE OF DIALKYL CARBAMOYL CHLORIDE IN THE PREVENTION AND TREATMENT OF BIOFILM IN WOUNDS

Paula de Souza Silva Freitas<sup>1,\*</sup> , Lucas Dalvi Armond Rezende<sup>2</sup> , Kelly Eduarda de Jesus Silva<sup>2</sup> ,  
Bruno Henrique Fiorin<sup>1</sup> , Ramon Araújo dos Santos<sup>1</sup> , Aline de Oliveira Ramalho<sup>3</sup> 

### ABSTRACT

**Objectives:** The aim was to identify the benefits of using Dialkyl Carbamoyl Chloride for the treatment of biofilms in wounds. **Methods:** This is an integrative literature review that aimed to answer the guiding question: "What are the benefits of using Dialkyl Carbamoyl Chloride in the healing of skin lesions?". The article selection stages resulted in 13 articles included. **Results:** The selected articles were grouped into two groups, namely: prevention and treatment of infection in wounds and prevention of surgical site infection, with nine productions in the first group and four in the second. Studies have shown that Dialkyl Carbamoyl Chloride attenuates colonization symptoms, such as odor, pain complaints and oozing, in addition to aiding in the prophylactic management of wound biofilm. Evidence indicates that dressings with Dialkyl Carbamoyl Chloride have no adverse effects, making them viable and safe options for chronic, acute and, mainly, infected injuries. **Conclusion:** It was identified that Dialkyl Carbamoyl Chloride was able to promote beneficial actions in the treatment of wounds, especially those of greater complexity. The proper choice of dressings and coverings can contribute to the rational use of existing technologies and antimicrobials, culminating in cost reduction and promotion of quality of life for individuals with chronic wounds.

**DESCRIPTORS:** Healing. Wounds and injuries. Infection Control. Stomatherapy.

## UTILIZAÇÃO DO CLORETO DE DIALQUIL CARBAMOIL NA PREVENÇÃO E TRATAMENTO DE BIOFILME EM FERIDAS

### RESUMO

**Objetivos:** Objetivou-se identificar os benefícios na utilização do Cloreto de Dialquil Carbamoil para tratamento de biofilmes em feridas. **Métodos:** Trata-se de uma revisão integrativa de literatura que visou responder à questão norteadora: "Quais os benefícios do uso de Cloreto de Dialquil Carbamoil na cicatrização de lesões de pele?". As etapas de seleção dos artigos resultaram em 13 artigos inclusos. **Resultados:** Os artigos selecionados foram agrupados em dois grupos, a saber: prevenção e tratamento de infecção em feridas e prevenção de infecção de sítio cirúrgico, sendo nove produções no primeiro grupo e quatro no segundo. Os estudos demonstraram que o Cloreto de Dialquil Carbamoil atenua os sintomas de colonização, como odor, queixas algicas e exsudação, além disso, auxilia no gerenciamento profilático do biofilme da ferida. As evidências apontam que coberturas com Cloreto de Dialquil Carbamoil não possuem efeitos adversos, tornando-se opções viáveis e seguras para lesões crônicas, agudas e, principalmente, infectadas. **Conclusão:** Identificou-se que o

1. Universidade Federal do Espírito Santo – Programa de Pós-graduação em Enfermagem – Vitória (ES), Brazil.
2. Universidade Federal do Espírito Santo – Centro de Ciências da Saúde – Departamento de Enfermagem – Vitória (ES), Brazil.
3. Universidade de São Paulo – Escola de Enfermagem – Hospital Sírio Libanês – São Paulo (SP), Brazil.

\*Correspondence author: paulassfreitas@gmail.com

Section Editor: Manuela M F Coelho

Received: Apr. 2021, 23 | Accepted: Jun. 2021, 23

How to cite: Freitas PSS; Rezende LDA; Silva KEJ; Fiorin BH; Santos RA; Ramalho AO. Use of Dialkyl Carbamoyl Chloride in the prevention and treatment of biofilm in wounds. ESTIMA, Braz. J. Enterostomal Ther., 2021, 19: e1621. [https://doi.org/10.30886/estima.v19.1087\\_IN](https://doi.org/10.30886/estima.v19.1087_IN)

Cloreto de Dialquil Carbamoil foi capaz de promover ações benéficas ao tratamento de feridas, especialmente as de maior complexidade. A escolha adequada das coberturas e dos curativos pode contribuir com a utilização racional das tecnologias existentes e dos antimicrobianos, culminando em redução de custos e promoção de qualidade de vida aos indivíduos com feridas crônicas.

**DESCRITORES:** Cicatrização. Ferimentos e lesões. Controle de infecções. Estomaterapia.

## USO DE CLORURO DE DIALQUIL CARBAMOIL EN LA PREVENCIÓN Y TRATAMIENTO DE BIOFILM EN HERIDAS

### RESUMEN

**Objetivos:** El objetivo fue identificar los beneficios del uso de Cloruro de dialquil carbamoil para tratar biopelículas en heridas. **Métodos:** Se trata de una revisión integradora de la literatura, cuyo objetivo es responder a la siguiente pregunta orientadora: “¿Cuáles son los beneficios del uso de Cloruro de dialquil carbamoil en la cura de lesiones cutáneas?”. Los pasos para seleccionar los artículos dieron como resultado 13 artículos incluidos. **Resultados:** Los artículos seleccionados se agruparon en dos grupos, a saber: Prevención y tratamiento de la infección en heridas y Prevención de la infección del sitio quirúrgico, con 9 producciones en el primer grupo y 4 en el segundo. Los estudios demostraron que Cloruro de dialquil carbamoil atenúa los síntomas de la colonización, como el olor, el dolor y la exudación, además, ayuda en el manejo profiláctico de la biopelícula de la herida. La evidencia apunta a que la cobertura Cloruro de dialquil carbamoil no tiene efectos adversos, lo que la convierte en opciones viables y seguras para lesiones crónicas, agudas y principalmente infectadas. **Conclusión:** Se identificó que la Cloruro de dialquil carbamoil fue capaz de promover acciones beneficiosas para el tratamiento de heridas, especialmente las de mayor complejidad. La elección adecuada de cubiertas y apósitos puede contribuir al uso racional de las tecnologías y los antimicrobianos existentes, culminando en la reducción de costos y la promoción de la calidad de vida de las personas con heridas crónicas.

**DESCRIPTORES:** Cicatrización de Heridas. Heridas y Traumatismos. Control de infección.

## INTRODUCTION

Difficult healing wounds are a global public health problem. It is known that several factors interfere in the healing process, and the intrinsic and extrinsic aspects of the patient should be considered in their assessment. However, it is recognized that most lesions with delayed or impaired healing are associated with the presence of biofilm<sup>1,2</sup>.

Microbial biofilms are defined as a group of microorganisms (MO) surrounded by a protective polymeric matrix and adhered to a surface, which can be either biotic or abiotic, formed from one or multiple species of MO<sup>3</sup>. Biofilm commonly presents in the wound bed with devitalized tissue and present in white cell protein exudate. Among the main clinical indicators of lesions with biofilm, there are lesions with induration, erythema and increase in exudate, in addition to pain complaints related to the wound. Biofilms are able to reconstitute themselves in the short term, due to the secretion of polymers and host components, indicating the need for regular cleaning of the lesion<sup>4</sup>.

The fact that biofilm is able to quickly reconstitute itself in the wound bed becomes a limiting factor for its management exclusively through mechanical debridement<sup>2</sup>. Thus, the adoption of structured care is recommended, aimed at removing the biofilm already installed in the bed, as well as the use of strategies that prevent further formation of this microbial conglomerate<sup>4</sup>.

In this context, several technologies have been developed with a focus on the management of biofilm and wound infection, among them we have Dialkyl Carbamoyl Chloride, also known as DACC, which is considered a local antimicrobial, as its pharmacological mechanism is the sequestration of microorganisms into the dressing through simple chemical bonds<sup>5</sup>.

## OBJECTIVES

The objective was to identify the benefits of using D ACC to treat biofilms in wounds.

## METHOD

This is an integrative literature review, following the six main steps for its preparation, namely: synthesis of the topic to be studied, implementation of the inclusion and exclusion criteria, identification of selected studies for review, categorization and analysis of studies, interpretation of results and summary of the review<sup>6</sup>.

To delimit the guiding question, the PICO strategy was used, which is summarized as: P – Population (People with skin lesions), I – Intervention (Use of DACC), C – Comparison/Control (Conventional therapy) and O - Outcomes (Healing)<sup>7</sup>. Given the above, this strategy promoted the formulation of the following guiding question: “What are the benefits of using Dialkyl Carbamoyl Chloride in the healing of skin lesions?”.

After defining the guiding question, the literature search was carried out through the following databases: Cumulative Index to Nursing and Allied (CINAHL), National Library of Medicine (PubMed) and Cochrane library. The search in the databases took place in November 2020, and to compose the search strategy, the Descritores de Ciência em Saúde/ Medical Subject Headings (DECS/MeSH) in English and Portuguese, separated by the Boolean operator “AND”, they are: “Wound” (“*Ferimentos e lesões*”), “Wound Healing” (“*Cicatrização*”), added to the keyword “Dialkyl Carbamoyl Chloride” (“*Cloreto de Dialquilcarbamoi*”).

The inclusion criteria for this review were defined as: publications from the last 10 years (2010 to 2020), in English, Spanish and Portuguese, including all types of studies and texts, available in full or not, excluding the productions that are repeated in the databases and those that did not answer the question of this research, preprints and letters to the editor. The article selection steps are shown in Fig. 1.

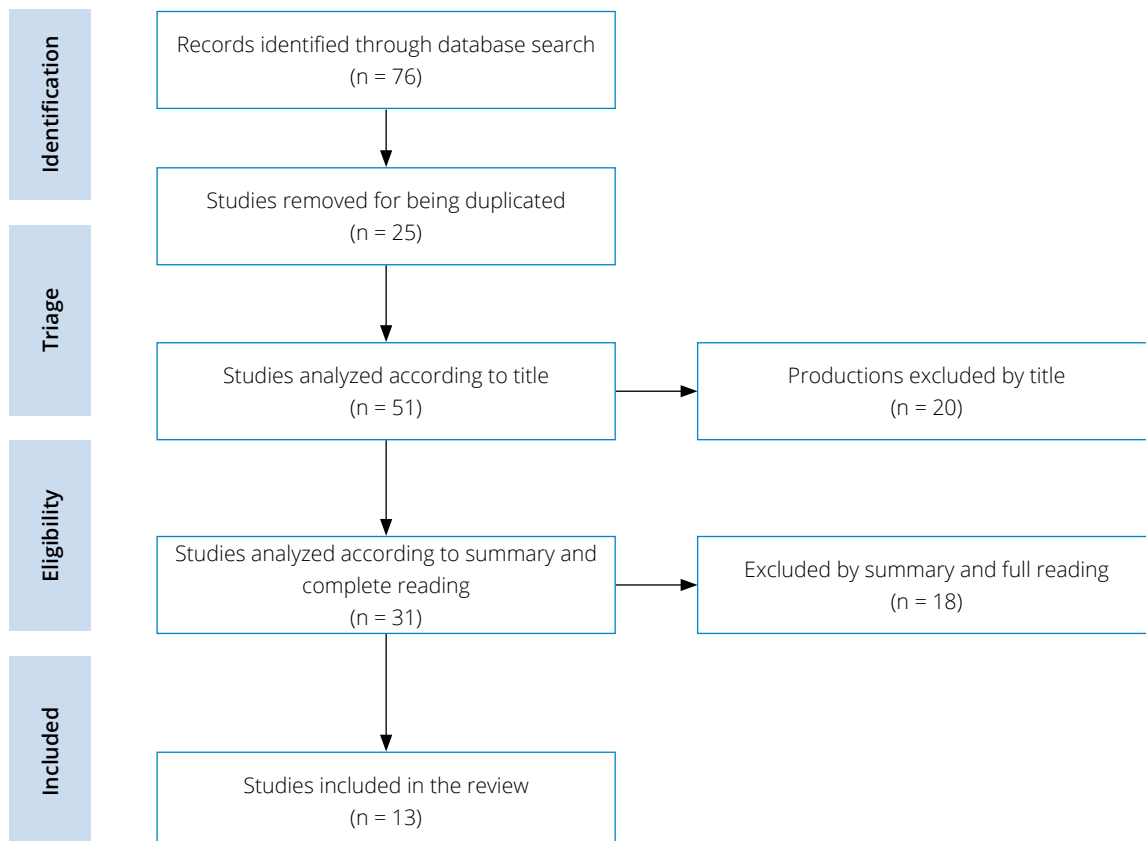


Figure 1. Organizational chart for selection of articles. Vitória (ES) – 2020.

In order to minimize probable errors or biases, the selection was carried out by two reviewers, independently and organized in two stages. In the first stage, the title and abstract were read, and in the second, the full text was read. In cases where there were disagreements, there was a discussion with the research supervisor about the inclusion or exclusion of the publication in the review (third reviewer).

After a complete reading of the publications included in this review, they were summarized in a Microsoft Word Office 365 document, containing: year of publication, name(s) of author(s), publication title, type of research, language, number of study participants, classification and brief summary about the content of the article, with step number 4.

## RESULTS

The synthesis of the findings was organized and divided according to the etiological types of the lesions studied in the articles, being the surgical site, wounds with no defined etiology and wounds in pediatric patients, shown sequentially in Table 1, Table 2 and Table 3. From the material surveyed, it was possible to group the results by semantic similarity, leading to the characterization of the articles into two groups: A) Prevention and treatment of wound infection and B) Prevention of surgical site infection.

According to the above characterization, it was noted that 4 productions (30.76%) were grouped in the surgical site infection prevention group and 9 articles (69.23%) were grouped in the prevention and treatment of wound infection.

Furthermore, an important relevance was noted in the productions that addressed pediatric patients, totaling 2 productions (15.38%). Regarding the year of publication, 3 of them were in the year 2019 (23.1%), 3 in the year 2017 (23.1%), 3 in the year 2012 (23.1%), 2 in the year 2016 (15.4%), 1 in 2018 (7.7%) and 1 year in 2020 (7.7%). Furthermore, based on the analysis of the language profile found, it was noted that all productions were published in English.

**Table 1.** Summary of selected articles on surgical wounds. Vitória (ES) – 2020.

Title	Category and Wound Studied	Author/ Year	Kind of Study	Language	Brief Conclusion
Dialkylcarbamoil chloride dressings in the prevention of surgical site infections after nonimplant vascular surgery.	Prevention of surgical site infection\vascular implant surgical site	Bua N et al., 2017	Prospective, comparative and non-randomized study with 200 participants.	English	It has effects in preventing surgical site infection in many different patient groups and may have a significant role in the future treatment of surgical wounds.
Reducing SSI rates for women birthing by caesarean section.	Prevention of surgical site infection\Cesarean surgical site	Taylor L et al., 2016	Multifaceted case study without information on the number of participants.	English	Decrease in the incidence of surgical site infection in women after cesarean section and promotion of cost reduction.
A pilot feasibility randomised clinical trial comparing dialkylcarbamoilchloride-coated dressings versus standard care for the primary prevention of surgical site infection.	Prevention of surgical site infection\Closed incisional wounds	Totty JP. et al., 2019	Pilot feasibility randomized clinical trial with 114 patients.	English	There were no adverse reactions, being considered tolerable, effective and cost-effective.
Prospective cohort study on surgical wounds comparing a polyhexanide-containing biocellulose dressing with a dialkyl-carbamoil-chloride-containing hydrophobic dressing.	Prevention of surgical site infection\Surgical wounds healed by 2 <sup>nd</sup> intention	Nilsen AM and Andriessen A, 2012	Prospective cohort study with 60 patients.	English	Apontou melhora do sítio cirúrgico e não houve melhora das taxas algicas.
Dialkylcarbamoil chloride-coated versus alginate dressings after pilonidal sinus excision: a randomized clinical trial (SORKYSA study).	Prevention and treatment of wound infection\Surgical wound by pilonidal sinus excision	Romain B. et al., 2020	Multicenter randomized study with 246 patients.	English	It showed improvement in the surgical site and there was no improvement in pain rates.

**Table 2.** Summary of selected articles without defined etiology. Vitória (ES) – 2020.

Title	Category and Wound Studied	Author/ Year	Kind of Study	Language	Brief Conclusion
Dialkylcarbamoyl chloride (DACC)-coated dressings in the management and prevention of wound infection: a systematic review.	Prevention and treatment of infected wounds\No specific definition of the etiology of the lesion	Totty J.P et al., 2017	Systematic review	English	Use in the prevention and treatment of infected wounds is encouraged as there are no adverse effects.
Infection management: The use of DACC-coated dressings in the management of wound infection.	Prevention and treatment of infected wounds\No specific definition of the etiology of the lesion	Meuleneire F, 2017	Literature review	English	The use has demonstrated the ability to manage the bioburden in different types of wounds, including complex wounds, preventing a deterioration of the wound picture and resulting in healing.
Bacterial-binding dressings in the management of wound healing and infection prevention: a narrative review.	Prevention and treatment of infected wounds\No specific definition of the etiology of the lesion	Chadwick P. e Ousey K, 2019	Literature review	English	Its use promotes greater benefit in prophylaxis and reduction of bacterial bioburden.
A comparison between DACC with chlorhexidine acetate-soaked paraffin gauze and foam dressing for skin graft donor sites.	Prevention and treatment of infected wounds\No specific definition of the etiology of the lesion	Lee J.W. et al., 2018	Retrospective study with 60 patients.	English	The associated use of paraffin gauze soaked in chlorhexidine in donor areas of skin graft, decreased healing time and was effective in infected lesions.
Using Cutimed® Sorbact® Hydroactive on chronic infected wounds.	Prevention and treatment of infected wounds\No specific definition of the etiology of the lesion	Bruce Z, 2012	Multicenter clinical study without information on the number of participants.	English	There was improvement in the injury and symptoms, especially when used in chronic injuries.
Clinical efficacy of dialkylcarbamoylchloride-coated cotton acetate dressing versus combination of normal saline dressing and 2% mupirocin ointment in infected wounds of epidermolysis bullosa.	Prevention and treatment of infected wounds\ Epidermolysis bullosa	Dwiyana RF et al., 2019	Randomized blind trial with 14 patients.	English	It promoted faster wound closure and was as effective as the combination of a dressing with normal saline and 2% mupirocin ointment.

**Table 3.** Summary of selected articles on pediatric wounds. Vitória (ES) – 2020.

Title	Category and Wound Studied	Author/ Year	Kind of Study	Language	Brief Conclusion
Infection management: Antimicrobial management for children with epidermolysis bullosa.	Prevention and treatment of infected wounds\Pediatric Epidermolysis bullosa	Denyer J, 2012	Literature review	English	Improved the look of the injuries and promoted load bacterial decrease.
Efficacy of Dialkylcarbamoylchloride-Coated Dressing in Management of colonize for Infected Neonatal and Pediatric Wounds.	Prevention and treatment of infected wounds\No specific delimitation of injury etiology in pediatrics	Boyar V, 2016	Systematic review	English	Promoted bacteriostatic activity without creating cytotoxicity or inflammatory response. The injury was healed between 2 and 4 weeks.

## DISCUSSION

Careful assessment of the wound, considering not only the injury, but also the patient's general condition and aspects related to the environment and access to health services, are essential for the success of the instituted treatment.

The microbial load of wounds has been a topic of discussion for many years. Nowadays, this theme has been advancing as microorganisms are more resistant to therapies with topical and/or systemic antibiotics. Given the overuse of antibiotics and the lack of evidence to support their clinical effectiveness in chronic wounds that do not heal, there is a need to develop therapies to overcome current barriers to healing in treating wounds caused by the ineffectiveness of antibiotics in infections of antimicrobial resistant lesions<sup>8-11</sup>. The use of systemic antibiotics, however, is recommended for deep or systemic infections, and may improve wound healing when appropriately indicated<sup>8-10</sup>.

With regard to classic topical antimicrobial therapy with the use of antibiotic products such as ointments, sprays and alike, despite having some direct action on wound bacteria, there is also the possibility of bacterial resistance, in addition to inducing hypersensitivity reactions and superinfections<sup>8,9</sup>.

Considering therapies with low risk of generating microbial resistance, new products have been developed for the topical treatment of wounds, with the objective of promoting the interruption of the initial adhesion process of microorganisms to the wound bed, among these, the DACC stands out, a fatty acid derivative that acts as a passive antibacterial, in order to sequester the bacteria into the dressing through hydrophobic bonds on the microorganism's extracellular surface, promoting irreversible adherence to the DACC substrate<sup>12-14</sup>.

From the analysis of the results, there is a consensus regarding the benefits of using DACC for the management of biofilms in wounds. Furthermore, its use can accelerate the healing process when compared to the use of alginate, and it can be used as a prophylactic coverage for the development of infection<sup>14</sup>.

The DACC demonstrated, *in vitro*, the ability to bind to several pathological microorganisms, including *Pseudomonas aeruginosa* and methicillin-resistant *Staphylococcus aureus* (MRSA), having a bactericidal and bacteriostatic effect<sup>5</sup>. In addition, evidence demonstrates that the product provides bacteriostatic activity, however, without generating cytotoxicity, being considered an alternative and accessible route for the healing of infected lesions or contaminated with large amounts of biofilm<sup>12,15</sup>.

Another interesting aspect is the versatility of coverings with DACC. Studies show its use in several situations, one of them in the post-surgical excision of the pilonidal sinus, which is considered a common condition that affects young adults, being characterized by the appearance of hair follicles in the natal cleft of the sacrococcygeal area, generating infection, discomfort and pain complaints, in which treatment options are limited to surgical excision with healing by second intention<sup>16</sup>. Studies such as the SOKYSA study (2020) demonstrate the effectiveness of using DACC in infected lesions, especially after pilonidal sinus excision. In the aforementioned study, DACC was compared to the use of alginate after excision. During dermatological follow-up, alginate-coated lesions showed a greater amount of slough compared to lesions coated with DACC. In relation to healing, the group with DACC had greater success, evolving to healing in up to 75 days<sup>14</sup>.

Another use of DACC is as a prophylactic coverage. A prospective, non-randomized and comparative study, in a vascular surgery center, with 200 participants who received dressings coated with DACC, showed a clear improvement in the number of patients with an infected surgical site using dressings with DACC when compared to conventional therapy<sup>17</sup>.

Another indication described was in cases of epidermolysis bullosa, being compared to the treatment of saline solution and 2% mupirocin correlates, demonstrating an improvement equivalent to traditional antimicrobial therapy, possibly being considered an alternative for patients who have adverse reactions to the use of mupirocin a 2%, as DACC has no known secondary reactions<sup>18</sup>.

Corroborating the study by Dwiyana (2019), a group of researchers, in 2012, evaluated the quantitative profile of bacterial bioburden in patients with lesions caused by epidermolysis bullosa, in which they presented a permissive narrative of the use of DACC for a long period, stating that there is attenuation of symptoms of intense colonization, such as odor, pain complaints and exudation, in addition, benefiting the prophylactic management of the wound biofilm<sup>19</sup>.

Furthermore, the use of DACC in complex lesions has been advised, since the pathogens are not destroyed, but stored, with no risk of accumulation of cellular debris in the lesion, which could lead to an exacerbation of the local inflammatory response, leading to tissue repair pain and dysfunction<sup>5,18,19</sup>, and given the evidence described that coverages with DACC do not have adverse effects, they become viable options for chronic, acute and, mainly, infected injuries<sup>12</sup>.

In a multicenter study conducted in England and Ireland, they sought to assess the evolution of skin lesions in areas of erythema, edema, pain, odor and exudate, being used in a variety of patients with dichotomous lesions, such as venous ulcers, traumatic lesions and mixed ulcers. Its outcome showed a decrease in the number of lesions with signs of inflammation (79% to 29%), in addition to an increase in the number of lesions with epithelial tissues and granulation tissues in patients using dressings with DACC<sup>20</sup>.

The use of DACC with paraffin gauze soaked with chlorhexidine acetate in skin graft donation sites showed contributing characteristics to healing, reducing healing time, being effective and recommended in the treatment of infected wounds<sup>21</sup>.

In Brazil, dressings impregnated with DACC are available in the form of swabs, indicated for mechanical debridement and removal of biofilm, in the form of a compress and impregnated in multilayer dressings with silicone edges<sup>3</sup>.

With technological advances and the increase in the arsenal of technologies for wound treatment, it is essential that health professionals, especially nurses, have knowledge about the applicability of the various dressings and the possible expected results, so that the management of skin injuries, especially those of greater complexity, can be done assertively and considering cost-effectiveness.

## CONCLUSION

It was identified that the DACC was able to promote beneficial actions regarding the treatment of wounds, especially those of greater complexity. Its role in microbial management stands out, whether for the prevention of surgical site infection, or for the treatment of infected wounds or with biofilm.

The proper choice of coverings and dressings can contribute to a more rational use of existing technologies and antibiotics (so controversial in clinical practice), culminating in cost reduction for the health system and promoting better quality of life for individuals who suffer from chronic wounds.

The limitation in the amount of research published on the subject is highlighted, with studies with a limited number of participants. Thus, it is extremely important to carry out further investigations that expand the use of this technology to other types of wounds and consider its cost-benefit and applicability.

## AUTHORS' CONTRIBUTION

**Conceptualization:** Freitas PSS e Ramalho AO; **Methodology:** Rezende LDA, Freitas PSS, Ramalho AO; **Research:** Rezende LDA e Silva KEJ; **Writing – First version:** Rezende LDA e Silva KEJ. **Writing – Revision & Editing:** Santos RA, Freitas PSS, Ramalho AO, Fiorin BH e Santos RA; **Supervision:** Freitas PSS e Ramalho AO.

## DATA STATEMENT AVAILABILITY

Data will be made available on request.

## REFERENCES

1. Malone M, Bjarnsholt T, McBain AJ, James GA, Stoodley P, Leaper D et al. The prevalence of biofilms in chronic wounds: a systematic review and meta-analysis of published data. *J Wound Care*. 2017;26(1):20–5. <https://doi.org/10.12968/jowc.2017.26.1.20>

2. Murphy C, Atkin L, Swanson T, Tachi M, Tan YK, Vega M et al. Consensus Document. Abordar feridas de difícil cicatrização com uma estratégia de intervenção precoce antibiofilme: higienização da ferida. *J Wound Care* 2020;29(Suppl3b):s1-s28. Available at: [https://www.woundhygiene.com/media/bs3bxuod/portugal\\_jwc\\_convatec\\_wound-hygiene-28pp\\_14-feb\\_ca-por.pdf](https://www.woundhygiene.com/media/bs3bxuod/portugal_jwc_convatec_wound-hygiene-28pp_14-feb_ca-por.pdf)
3. Jones CM, Rothermel AT, Mackay DR. Evidence-Based Medicine: Wound Management. *Plast Reconstr Surg*. 2017;140(1):201e-216e. <https://doi.org/10.1097/PRS.00000000000003486>
4. Viviana SGC, Thum M, Aline OR, Beloto Silva O, Franco Coelho M, Medeiros da Silva Queiroz W et al. Analysis of "1st Brazilian Recommendation for Biofilm Management in Chronic and Complex Wounds." *ESTIMA, Braz J Enterostomal Ther*. 2019;17:e1819. [https://doi.org/https://doi.org/10.30886/estima.v17.783\\_IN](https://doi.org/https://doi.org/10.30886/estima.v17.783_IN)
5. Totty JP, Hitchman LH, Cai PL, Harwood AE, Wallace T, Carradice D et al. A pilot feasibility randomised clinical trial comparing dialkylcarbamoylechloride-coated dressings versus standard care for the primary prevention of surgical site infection. *Int Wound J*. 2019;16(4):883-90. <https://doi.org/10.1111/iwj.13113>
6. Botelho LLR, Cunha CC de A, Macedo M. O Método Da Revisão Integrativa Nos Estudos Organizacionais. *Gestão e Sociedade*. 2011;5(11):121-136. <https://doi.org/10.21171/ges.v5i11.1220>
7. Galvão TF, Pereira MG. Revisões sistemáticas da literatura: passos para sua elaboração. *Epidemiol e Servi Saúde*. 2014;23(1):183-4. <http://doi.org/10.5123/S1679-49742014000100018>
8. Pinto AM, Cerqueira MA, Bañobre-López M, Pastrana LM, Sillankorva S. Bacteriophages for Chronic Wound Treatment: from Traditional to Novel Delivery Systems. *Viruses*. 2020;12(2):235. <https://doi.org/10.3390/v12020235>
9. Powers JG, Higham C, Broussard K, Phillips TJ. Wound healing and treating wounds: Chronic wound care and management. *J Am Acad Dermatol*. 2016;74(4):607-25. <https://doi.org/10.1016/j.jaad.2015.08.070>
10. Bowler PG. Antibiotic resistance and biofilm tolerance: a combined threat in the treatment of chronic infections. *J Wound Care*. 2018;27(5):273-7. <https://doi.org/10.12968/jowc.2018.27.5.273>
11. Pieper B, Sobek J, Kaljee L, Templin TN. A Descriptive Study Using an Intercept Survey: Knowledge, Attitudes, Beliefs, and Behaviors About Systemic Antibiotic Use in Adults Who Reported a Wound Within the Previous Year. *J Wound Ostomy Continence Nurs*. 2020;47(1):20-5. <https://doi.org/10.1097/WON.0000000000000612>
12. Meuleneire F. Infection management: The use of DACC-coated dressings in the management of wound infection. *Br J Nurs*. 2012;21(Sup2):4-7. <https://doi.org/10.12968/bjon.2012.21.Sup2.4>
13. Chadwick P, Ousey K. Bacterial-binding dressings in the management of wound healing and infection prevention: a narrative review. *J Wound Care*. 2019;28(6):370-82. <https://doi.org/10.12968/jowc.2019.28.6.370>
14. Romain B, Mielcarek M, Delhorme JB, Meyer N, Brigand C, Rohr S et al. Dialkylcarbamoyle chloride-coated versus alginate dressings after pilonidal sinus excision: a randomized clinical trial (SORKYSA study). *BJS open*. 2020;4(2):225-31. <https://doi.org/10.1002/bjs5.50259>
15. Boyar V. Efficacy of dialkylcarbamoylechloride-coated dressing in management of colonized or infected neonatal and pediatric wounds. *J Wound Ostomy Continence Nurs*. 2016;43(5):547-50. <https://doi.org/10.1097/WON.0000000000000266>
16. Biter LU, Beck GMN, Mannaerts GHH, Stok MM, Ham AC, Grotenhuis BA. The use of negative-pressure wound therapy in pilonidal sinus disease: a randomized controlled trial comparing negative-pressure wound therapy versus standard open wound care after surgical excision. *Dis Colon Rectum*. 2014;57(12):1406-11. <https://doi.org/10.1097/DCR.0000000000000240>
17. Bua N, Smith GE, Totty JP, Pan D, Wallace T, Carradice D et al. Dialkylcarbamoyle Chloride Dressings in the Prevention of Surgical Site Infections after Nonimplant Vascular Surgery. *Ann Vasc Surg*. 2017;44:387-92. <https://doi.org/10.1016/j.avsg.2017.03.198>
18. Dwiyana RF, Gondokaryono SP, Rahardja JI, Diana IA, Yogya Y, Gunawan H. Clinical efficacy of dialkylcarbamoylechloride-coated cotton acetate dressing versus combination of normal saline dressing and 2% mupirocin ointment in infected wounds of epidermolysis bullosa. *Dermatol Ther*. 2019;32(5):e13047. <https://doi.org/10.1111/dth.13047>
19. Denyer J. Infection management: Antimicrobial management for children with epidermolysis bullosa. *Br J Nurs*. 2012;21(Sup2):8-10. <https://doi.org/10.12968/bjon.2012.21.Sup2.8>
20. Bruce Z. Using Cutimed® Sorbact® hydroactive on chronic infected wounds. *Wounds UK*. 2012;8(1):119-29. Available at: [https://www.researchgate.net/publication/286986985\\_Using\\_CutimedR\\_SorbactR\\_hydroactive\\_on\\_chronic\\_infected\\_wounds](https://www.researchgate.net/publication/286986985_Using_CutimedR_SorbactR_hydroactive_on_chronic_infected_wounds)
21. Lee JW, Park SH, Suh IS, Jeong HS. A comparison between DACC with chlorhexidine acetate-soaked paraffin gauze and foam dressing for skin graft donor sites. *J Wound Care*. 2018;27(1):28-35. <https://doi.org/10.12968/jowc.2018.27.1.28>